

Congenital anonychia and brachydactyly of the left foot - Cooks syndrome variant: Case report and review of literature

Daipayan Chatterjee

Department of Orthopaedics, Vardhaman Mahavir Medical College and Safdarjung Hospital, New Delhi, India

Cooks syndrome is characterized by familial congenital anonychia or onychodystrophy, hypoplasia or absence of distal phalanges of the hands and feet with brachydactyly of the fifth finger and digitalization of the thumb (triphalangism). It is listed as a "rare disease" by the Office of Rare Diseases of the National Institutes of Health. Here, we report a case of congenital anonychia and brachydactyly of the left foot, which possibly is a variant of Cooks syndrome with a positive family history of similar deformity.

Key words: Brachydactyly, congenital anonychia, Cooks syndrome, congenital anonychia, familial, rare disease

Introduction

Cooks syndrome is characterized by familial congenital anonychia or onychodystrophy, hypoplasia or absence of distal phalanges of the hands and feet with brachydactyly of the fifth finger and digitalization of the thumb (triphalangism).^[1] Cooks syndrome is listed as a "rare disease" by the Office of Rare Diseases of the National Institutes of Health (NIH). Here we report a case of congenital anonychia and brachydactyly of the left foot, which possibly is a variant of Cooks syndrome with a positive family history of similar deformity.

Case Report

A 45-year-old male came for orthopedics consultation at a tertiary center with congenital absence of nails of all the toes of the left foot. On examination, the toes of the left foot were found to be short and bulbous with anonychia and syndactyly between toe 2 and 3 [Figure 1]. Similar

abnormality was not observed in the hands or the right foot. No other skeletal anomaly was detected. Sexual development and higher motor function was normal. No facial anomaly was detected. Radiography revealed the absence of distal phalanx of all the toes of left foot, absence of the middle phalanx of toe 2, 3, 4 and a hypoplastic middle phalanx of little toe. Metatarsals were grossly normal [Figure 2]. Radiographs of the patella and that of bilateral hands and right foot were normal. The patient recalled the presence of similar abnormality, but involving unilateral feet in his late father (C-3 in pedigree), uncle (C-1 in pedigree) and grandfather (B-1 in pedigree). All available family members were examined. The proband was unmarried and had an unaffected brother. There was a history of consanguineous marriage in the family (B1-B2 in pedigree). The pedigree chart denotes male to male transmission with a probable autosomal dominant type of inheritance [Figure 3]. The patient's day to day activities were not compromised in any way by the anomaly and hence we chose to go with observation after explaining to the patient about the anomaly.

Discussion

Cook *et al.*^[1] described a syndrome characterized by onychodystrophy or anonychia, brachydactyly of the fifth finger, and digitalization of the thumbs, with absence or hypoplasia of the distal phalanges of the hands and feet. Seven individuals in two generations of the same family with one instance of male-to-male transmission with probable autosomal dominant transmission had the disorder. Nevin *et al.*^[2] described what they reported as

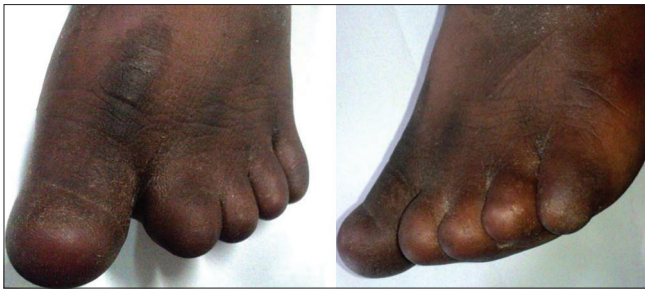

Figure 1: Clinical picture from the front and the sides of the left foot with anonychia, brachydactyly and syndactyly between 2nd and 3rd toe

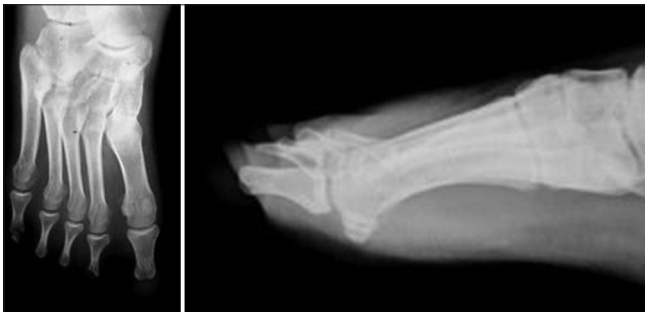

Figure 2: Radiograph anteroposterior and lateral views of left feet showing absence of distal phalanx of all the toes with absence of middle phalanx of toes 1-4, hypoplasia of the middle phalanx of 5th toe and normal metatarsals

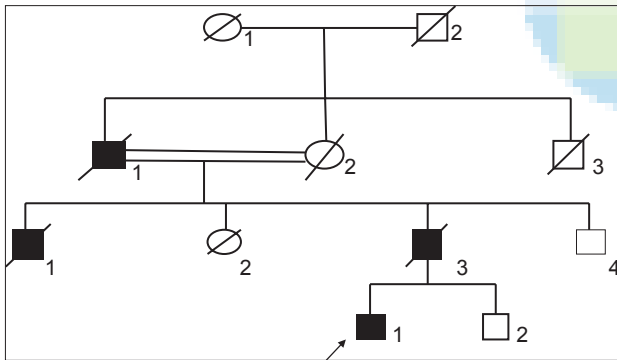


Figure 3: Pedigree chart showing proband (D-1) and affected members of the family (B-1), (C-1) and (C-3). Consanguineous marriage is evident between B-1 and B-2. Male to male transmission is evident two levels

the second family with Cooks syndrome and established it as a distinct entity. Four individuals in three successive generations were found to have bilateral anonychia of toes and 4th and 5th fingers of the hands with bilateral nail hypoplasia of digits 1-3 of hands along with brachydactyly. Castori *et al.*^[3] reported a 2-year-old Caucasian girl with Cooks syndrome having short fingers with hypoplastic distal flexion creases. Nails were absent on fingers 2 and 3, severely hypoplastic on fingers 1 and 4, and

moderately shortened on fingers 5. Cutaneous syndactyly of toes 2 and 3 and toes 2, 3, and 4 was evident on the left and right foot, respectively. Padmavathy *et al.* have reported a case of variant of Cooks syndrome affecting four digits of the right hand having brachydactyly and anonychia in a 40-year-old male. Kurth *et al.*^[4] reported 4 families of variants of Cooks syndrome with symmetric brachydactyly of the hands and feet, along with hyponychia or anonychia. Radiographs showed missing middle phalanges and elongated terminal and proximal phalanges. Brennan *et al.* reported a case of Cooks syndrome with congenital anonychia, absent distal phalanges, and rudimentary hypoplastic middle phalanges and brachydactyly of bilateral feet.^[5] The family reported here differs from other genetic disorders involving nail and bone dysplasias of the hands and feet. In autosomal dominant anonychia-onychodystrophy^[6] no bone changes had been described. Hobbs^[7] described an autosomal dominant nail dysplasia which was most marked in the first digit of the hands and feet. There were 11 affected family members with male to male transmission. Affected members showed an unusual tapering of the distal phalanx with a spatulate tip. The family described by Verbov,^[8] in addition to congenital anonychia, had hyper and hypopigmentation of the axillae and groins. Family with anonychia and ectrodactyly described by Kumar and Levik^[9] was characterized by relatively bizarre, asymmetric digital anomalies, including absence of one or more digits and hypoplasia of metacarpals and metatarsals, which distinguishes it from the reported case. In several genetic syndromes of congenital anonychia or onychodystrophy, other clinical features coexist such as hair and teeth anomalies,^[10] eye defects,^[11] deafness,^[12] joint contractures,^[13] mental retardation^[14] ectrodactyly^[15] and facial anomalies.^[16,17] Neither the family of Cooks *et al.*^[1] nor the present one had any of the aforementioned clinical features. In this case report, the patient has congenital anonychia with brachydactyly of the left foot with a positive family history in 4 individuals in 3 generations, male to male transmission and probable autosomal dominant inheritance resembling Cooks syndrome very closely. However, since all the extremities were not involved this anomaly may be considered to be a variant of Cooks syndrome.

References

1. Cooks RG, Hertz M, Katznelson MB, Goodman RM. A new nail dysplasia syndrome with onychonychia and absence and/or hypoplasia of distal phalanges. *Clin Genet* 1985;27:85-91.
2. Nevin NC, Thomas PS, Eedy DJ, Shepherd C. Anonychia and absence/hypoplasia of distal phalanges (Cooks syndrome): Report of a second family. *J Med Genet* 1995;32:638-41.
3. Castori M, Brancati F, Mingarelli R, Mundlos S, Dallapiccola B. A novel patient with Cooks syndrome supports splitting from "classic" brachydactyly type B. *Am J Med Genet A* 2007;143:195-9.
4. Kurth I, Klopocki E, Stricker S, van Oosterwijk J, Vanek S, Altmann J, *et al.* Duplications of noncoding elements 5' of SOX9 are associated with brachydactyly-anonychia. *Nat Genet* 2009;41:862-3.
5. Brennan CB, Buehler T, Leshner JL Jr. Cooks syndrome: A case report and brief review. *Pediatr Dermatol* 2013;30:e52-3.
6. Timerman I, Museteanu C, Simionescu NN. Dominant anonychia and onychodystrophy. *J Med Genet* 1969;6:105-6.
7. Hobbs ME. Hereditary onychial dysplasia. *Am J Med Sci* 1935;190:200-6.
8. Verbov J. Anonychia with bizarre flexural pigmentation-an autosomal dominant dermatosis. *Br J Dermatol* 1975;92:469-74.
9. Kumar D, Levick RK. Autosomal dominant onychodystrophy and anonychia with type B brachydactyly and ectrodactyly. *Clin Genet* 1986;30:219-25.
10. Pinheiro M, Pereira LC, Freire-Maia N. A previously undescribed condition: Tricho-odonto-onycho-dermal syndrome. A review of the tricho-odonto-onychial subgroup of ectodermal dysplasias. *Br J Dermatol* 1981;105:371-82.
11. Chemke J, Oliver M, Mallek D, Kaveh Z. Multiple ophthalmic anomalies and digital hypoplasia. *J Genet Hum* 1978;26:17-24.
12. Goodman RM, Lockareff S, Gwinup G. Hereditary congenital deafness with onychodystrophy. *Arch Otolaryngol* 1969;90:474-7.
13. Pfeiffer RA. The oto-onycho-peroneal syndrome. A probably new genetic entity. *Eur J Pediatr* 1982;138:317-20.
14. Nevin NC, Thomas PS, Calvert J, Reid MM. Deafness, onycho-osteodystrophy, mental retardation (D.O.O.R) syndrome. *Am J Med Genet* 1982;13:325-32.
15. Lees DH, Lawler SD, Renwick JH, Thoday JM. Anonychia with ectrodactyly: Clinical and linkage data. *Ann Hum Genet* 1957;22:69-79.
16. Houlston RS, Temple IK. Characteristic facies in type B brachydactyly? *Clin Dysmorphol* 1994;3:224-7.
17. Santos HG, George FH, Ferreira JR. Hereditary brachydactyly with nail aplasia. *Acta Med Port* 1981;3:147-60.

Cite this article as: Chatterjee D. Congenital anonychia and brachydactyly of the left foot - Cooks syndrome variant: Case report and review of literature. *Indian J Hum Genet* 2014;20:206-8.

Source of Support: Nil, **Conflict of Interest:** None declared.