

Phenotypical characterization of 13q deletion syndrome: Report of two cases

Eiman Bagherizadeh¹, Yousef Shafaghati¹, Fatemeh Hadipour¹, Farkhondeh Behjati^{1,2}

¹Department of Medical Genetics, Sarem Cell Research Center, Sarem Hospital, ²Genetics Research Center, University of Social Welfare and Rehabilitation Sciences, Tehran, Iran

Patients with 13q deletion syndrome are characterized with different phenotypical features depending on the size and location of the deleted region on chromosome 13. These patients fall into three groups: In Group 1, deleted region is in the proximal and does not extend into q32; in Group 2, deleted region involves proximal to the q32 and in Group 3 q33-q34 is deleted. We present two cases with 13q syndrome with two different deleted region and different severity on clinical features: One case with interstitial deletion belongs to the Group 1 with mild mental retardation and minor malformations and the other case with terminal deletion belongs to Group 3 with moderate to severe mental retardation and major malformations.

Key words: 13q deletion syndrome, mental retardation, multiple anomalies

and patients tend to appear with minor abnormalities, mild to moderate mental retardation and susceptible to retinoblastoma.^[3,4] Group 2 included those with proximal to q32 (q12.2-q32), these patients appear with major malfunctions, moderate to severe mental retardation and microcephaly^[5] and growth retardation. Group 3 comprised those with q33-q34; these patients have severe mental retardation without major malfunctions and growth retardation.^[1,2]

Case Reports

Case 1

A 5-year-old boy was referred for genetic counseling with different phenotypical features [Table 1]. The parents were unrelated with history of one abortion in the previous pregnancy. The patient was the product of a full-term pregnancy and normal vaginal delivery. Birth weight was 2.4 kg. He had seizure beginning from 2nd months; brain computed tomography (CT) scan displayed agenesis of vermis of the cerebellum [Figure 1], the clinical features in this case were:

Cleft palate, microcephaly (head circumference of 45 cm [<-2 SD (2%)]^[6]), moderate to severe mental retardation, speech difficulty, asymmetric in left skulp, ptosis, club feet, down slanted palperbal fissures, hypospadias, neurodevelopmental delay, syndactyly in both hands fingers, short metacarp, overriding of the fourth toes, strabismus, left blepharophimosis in the left side, high nasal bridge, thin lips, micrognathia, no ovala, dental decay, small ears, and hypoplastic thumb.

Introduction

Phenotypical features of chromosome 13q syndrome have been described over the past 30 years. The patients have various clinical features depending on the size and deleted region on chromosome 13. This region was investigated as a critical region for these patients.^[1,2] The 13q syndrome is characterized into 3 groups: Group 1 in which proximal region (q12.2-q31) is involved in deletion

Access this article online	
Quick Response Code:	Website: www.ijhg.com
	DOI: 10.4103/0971-6866.142912

Address for correspondence: Dr. Farkhondeh Behjati, Genetics Research Center, University of Social Welfare and Rehabilitation Sciences, Tehran, Iran. E-mail: f_behjati@uswr.ac.ir

Case 2

A 12-year-old girl was referred with dysmorphic features, mild mental retardation, and neurodevelopmental delay [Table 1]. The girl was the product of a normal pregnancy and birth weight and height were 3.5 kg and 49 cm, respectively. Head circumference was 53 cm normal for the age of 12 years, and she is studying in the elementary school. Parents were first cousins once removed with the history of one abortion in the mother. There are two other healthy male and female siblings in the family. She was evaluated by nerve conduction velocity test and exhibited some sort of neuropathy. Clinical characterizations included [Figure 2]: Generalized weakness of muscle bulk (hypotonia), scapula alata, upper limb girdle weakness, high nasal bridge, wide mandibular angle, high arched palate, thin and long narrow face, down slanted palpebral fissures, hypoplasia of alae nasi, low hairline, webbed neck, overriding toes, and sandal gap. There were small nevi on her posterior trunk.

Materials and Methods

Standard high-resolution GTG banding was carried out in order to investigate the patients' chromosomes. Metaphase chromosomes prepared on slides using pancreatin enzyme for banding preparation.

Results and Discussion

We present here two cases with 13q deletion syndrome

Table 1: Clinical features of the patients

Clinical description	Case 1	Case 2
Microcephaly	+	-
Hypertelorism	+	+
Seizure	+	-
Down slanted palpebral fissures	+	+
Syndactyly	+	-
Retinoblastoma	-	-
Moebius syndrome association	+	-
Neurodevelopmental delay	+	+
Expansion of deletion	q33-q34	q12.3-q14.3
Mental retardation	Moderate to severe	Mild
Club foot	+	-
Upper limb girdle weakness	-	+
Dental decay	+	-
High nasal bridge	+	+
Overriding toes	+	+
Equine valgus	+	-
Blepharophimosis	+	-
Scapula alata	-	+
Web neck	-	+

with different phenotypical features. Case 1, a boy with deletion of q33-q34 [Figure 3] who had microcephaly, moderate to severe mental retardation, neurodevelopmental delay, and primary diagnosis was Moebius syndrome. There was agenesis of vermis cerebellum after CT scan evaluation. Case 2 was a girl with deletion of q12.3-q14.3 [Figure 3], with dismorphic features, neurodevelopmental delay and neuropathy, but not microcephaly and seizure; this case did not have any retinoblastoma.

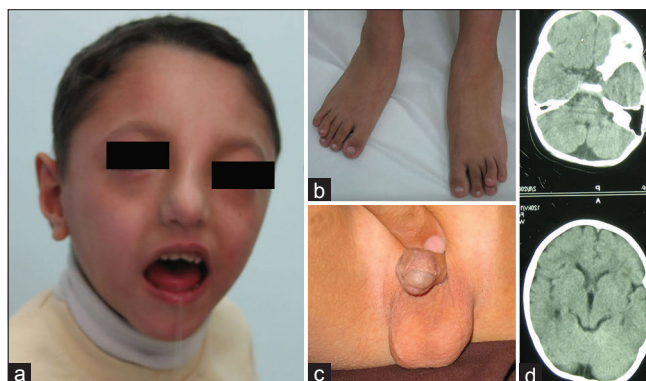


Figure 1: (a) Note to the ptosis, down slanted palpebral fissures, strabismus, and high nasal bridge. (b) Over riding of fourth toes. (c) Hypospadias. (d) Agenesis of the vermis cerebellum

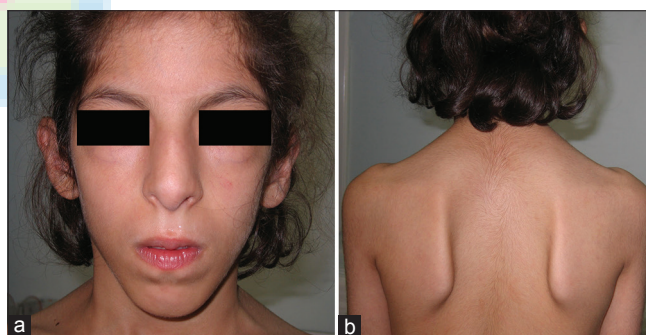

Figure 2: (a) Note to the high nasal bridge, wide mandibular angle, thin and long narrow face, down slanted palpebral fissures, web neck. (b) Scapula alata

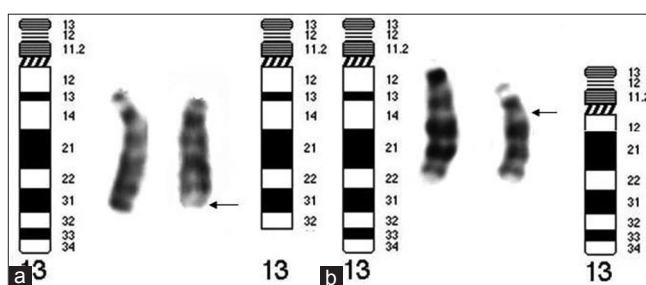


Figure 3: (a) The abnormal chromosome displays deleted region from q33 to q34 which, belongs to Group 3. (b) The abnormal chromosome, with deleted region of q12.3-q14.3 belongs to Group 1

Case 1 related to the Group 3 with more severe phenotypical and neurological features and Case 2 related to the Group 1 with less clinical and neurological characterizations. Overall Case 1 exhibited more dysmorphic characterizations and more severe mental retardation than Case 2. Our findings are consistent with previous cases reported. It is recommended that children with seizure, neuropathy, mental retardation, and dismorphic features can be the candidate for chromosomal investigation as well as other tests required for evaluation.

References

1. Brown S, Gersen S, Anyane-Yeboah K, Warburton D. Preliminary definition of a "critical region" of chromosome 13 in q32: report of 14 cases with 13q deletions and review of the literature. *Am J Med Genet* 1993;45:52-9.
2. Brown S, Russo J, Chitayat D, Warburton D. The 13q-syndrome: The molecular definition of a critical deletion region in band 13q32. *Am J Hum Genet* 1995;57:859-66.
3. Lele KP, Penrose LS, Stallard HB. Chromosome deletion in a case of retinoblastoma. *Ann Hum Genet* 1963;27:171-4.
4. Sparkes RS, Sparkes MC, Wilson MG, Towner JW, Benedict W, Murphree AL, *et al.* Regional assignment of genes for human esterase D and retinoblastoma to chromosome band 13q14. *Science* 1980;208:1042-4.
5. Fryns JP. Microcephaly/lymphedema and terminal deletion of the long arm of chromosome 13. *Am J Med Genet* 1995;57:504.
6. Jones KL. *Smith's Recognizable Patterns of Human Malformation*. 6th ed. Philadelphia: Elsevier-Saunders; 2006. p. 849.

Cite this article as: Bagherizadeh E, Shafaghati Y, Hadipour F, Behjati F. Phenotypical characterization of 13q deletion syndrome: Report of two cases. *Indian J Hum Genet* 2014;20:203-5.

Source of Support: Nil, **Conflict of Interest:** None declared.

