

Ectopia cilia with pedigree analysis: Second case report in the world

Tarang Goyal, Anupam Varshney¹, S. K. Bakshi²

Departments of Dermatology, Venereology and Leprosy, ¹Pathology, and ²Medicine, Muzaffarnagar Medical College and Hospital, Muzaffarnagar, Uttar Pradesh, India

We present a case of ectopia cilia in a 28-year-old male patient. Ectopia cilia were seen in the outer third of left upper eyelid. The patient's maternal grandfather also had ectopia cilia of the left upper eyelid as reported by the patient's mother. Ectopia cilia is a rare condition seen in humans. Only 12 cases of ectopic cilia in humans have been reported so far in the world. The present case of ectopia cilia is the second case report in the world with pedigree analysis.

Key words: Cilia incarnata, dermoid cyst, distichiasis, ectopia cilia, trichiasis

Introduction

Cilia (eyelashes) are unique hair follicles present at the eyelid margins. The ciliary abnormalities include agenesis, ciliary row duplication and ectopia cilia. Ectopia cilia are the rarest of ciliary anomalies. Only 12 human cases have been reported so far.

Case Report

A 28-year-old male patient came to our hospital outpatient department with complaints of short

hair (5-8 mm in length) coming out from the left upper eyelid since childhood as reported by his parents. A pre-operative diagnosis of ectopia cilia was made. On close examination by the dermatologist and the physician, the ectopia cilia was located 7 mm superior-lateral to the left upper lid margin. The ectopic lash bundle consisted of 11 hair follicles. The ectopic lash measured 4 mm at the base [Figure 1]. The patient's maternal grandfather (since deceased) had similar ectopia cilia on left upper eyelid as was reported by patient's mother [Figure 2].

An out-patient surgical excision procedure under local anesthesia was done.

An incision parallel to the lid margin was given and root of the tuft dissected. Histological findings were suggestive of eccrine sweat glands with no features of apocrine glands and dermoid cyst seen as reported by the pathologist. After 3 months follow-up, no recurrence was detected.

Discussion

The first case report of ectopia cilia was reported by Weigmann in 1936.^[1] The presentations in published works fall in two distinct categories: Cilia protruding from the anterior surface and cilia protruding from posterior surface of the tarsal plate. The anteriorly placed cilia are uniformly located on the lateral quarter of the upper eyelid and associated with the presence of apocrine sweat glands and are congenital in origin.^[2] Dalgleish^[3] presented two cases - one of them had large apocrine

Access this article online	
Quick Response Code:	Website: www.ijhg.com
	DOI: 10.4103/0971-6866.142897

Address for correspondence: Dr. Tarang Goyal, H. No. 40, Somdutt Vihar, Meerut - 250 004, Uttar Pradesh, India.
E-mail: tarang_derma@yahoo.co.in, tarangderma4121@gmail.com

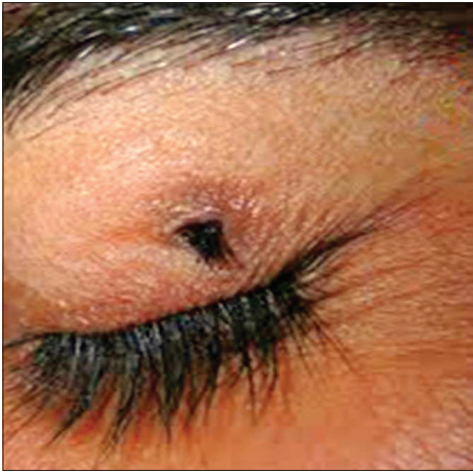

Figure 1: Ectopia cilia with eleven hair lash bundles

sweat glands attached to the follicle. Owen^[4] reported a case of ectopia cilia in a 14-year-old boy. Baghestani and Banihashemi^[5] reported first case of ectopia cilia with pedigree analysis in a 14-year-old Iranian boy with a positive history of the same anomaly in his paternal grandfather demonstrating evidence of an inherited genetic disorder. Gordon *et al.*^[6] reported that only nine cases of ectopia cilia have been reported so far till 1991.

The differential diagnosis of ectopia cilia includes several eyelash abnormalities such as cilia incarnata, a condition in which an extra eyelash grows from a normal origin through the eyelid to the inner aspect of the tarsal conjunctiva or outward to the skin. Dermoid cysts are the most common periorbital masses presenting in childhood. Wang *et al.*^[7] presented an unusual case of a dermoid cyst presenting with black hairs emerging from a sinus tract on the upper eyelid and mimicking the appearance of ectopic cilia.

Distichiasis and trichiasis are other conditions which also need to be differentiated from ectopia cilia. A distichia is an eyelash that arises from an abnormal spot on the eyelid. Distichiae usually exit from the duct of the meibomian gland at the eye margin. They are usually multiple and sometimes more than one arises from a duct. Trichiasis is a condition in which cilia originates from a normal position on the eyelid turn inward due to

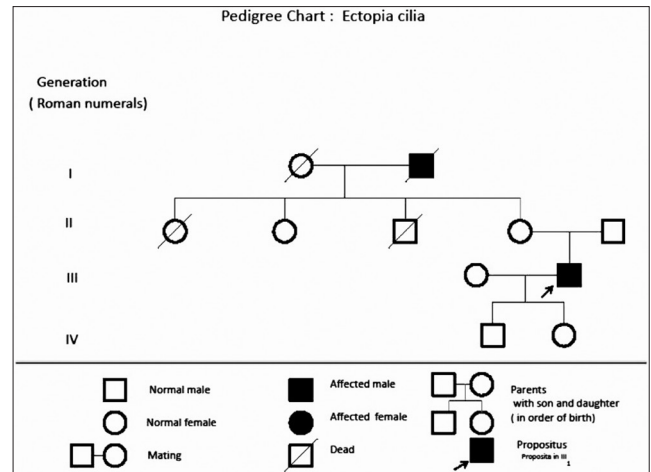


Figure 2: Pedigree chart of ectopia cilia

entropion. Trichiasis is most commonly associated with trachoma.^[8,9]

The nearness of tuft to the tarsal plate, the texture and the direction of the cilia suggest that the origin of the ectopia cilia may probably be related to the eyelashes in our patient.

References

1. Wiegmann E. *Klin. Mbl. Augenheilk* 1936;96:230.
2. Güler M, Yılmaz T, Güler O. A case of ectopic cilia. *Int Ophthalmol* 2009;29:297-8.
3. Dalgleish R. Ectopic cilia. *Br J Ophthalmol* 1966;50:592-4.
4. Owen RA. Ectopic cilia. *Br J Ophthalmol* 1968;52:280.
5. Baghestani S, Banihashemi SA. Ectopic cilia in a 14-year-old boy. *Pediatr Dermatol* 2011;28:55-6.
6. Gordon AJ, Patrinely JR, Knupp JA, Font RL. Complex choristoma of the eyelid containing ectopic cilia and lacrimal gland. *Ophthalmology* 1991;98:1547-50.
7. Wang Y, Su F, Li Y, Xiao L. Orbital dermoid cyst with sinus tract mimicking ectopic cilia. *J AAPOS* 2010;14:532-3.
8. Rajak SN, Collin JR, Burton MJ. Trachomatous trichiasis and its management in endemic countries. *Surv Ophthalmol* 2012;57:105-35.
9. Rajak SN, Habtamu E, Weiss HA, Bedri A, Gebre T, Genet A, *et al.* Epilation for trachomatous trichiasis and the risks of corneal opacification. *Ophthalmology* 2012;119:84-9.

Cite this article as: Goyal T, Varshney A, Bakshi SK. Ectopia cilia with pedigree analysis: Second case report in the world. *Indian J Hum Genet* 2014;20:185-6.

Source of Support: Nil, Conflict of Interest: None declared.