

Mayer-Rokitansky-Kuster-Hauser syndrome type II: A rare case

Anand Pai, Mohammad Shakir

Department of General Medicine, Aarupadai Veedu Medical College and Hospital, Puducherry, India

Mayer-Rokitansky-Kuster-Hauser (MRKH) is a malformation complex comprising absent vagina and absent or rudimentary uterus. MRKH syndrome may be attributed to an initial affection of the intermediate mesoderm consequently leading (by the end of the 4th week of fetal life) to an alteration of the blastema of the cervicothoracic somites and the pronephric ducts. These latter subsequently induce the differentiation of the mesonephric and then the Wolffian and Mullerian ducts. There are very sparse such cases reported. We present a case of type II MRKH or Mullerian renal cervical somite association (i.e., Mullerian duct aplasia, renal dysplasia, and cervical somite anomalies).

Key words: Dandy Walker malformation, mayer-rokitansky-kuster-hauser syndrome type II, mullerian agenesis, renal agenesis

various other syndromes or associations and thus, require accurate delineation. Since MRKH manifests itself in males, the term genital, renal, ear, skeletal syndrome might be more appropriate when applied to both sexes. The MRKH syndrome, when described in familial aggregates, seems to be transmitted as an autosomal dominant trait with an incomplete degree of the penetrance and variable expressivity. This suggests the involvement of either mutations in a major developmental gene or a limited chromosomal deletion. Until recently progress in understanding the genetics of MRKH syndrome has been slow, however, now HOX genes have been shown to play key roles in body patterning and organogenesis, and in particular during the genital tract development. Expression and or function defects of one or several HOX genes may account for this syndrome.

Introduction

The Mayer-Rokitansky-Kuster-Hauser (MRKH) syndrome affects at least 1 out of 4500 women and has for a long time been considered as a sporadic anomaly. Congenital absence of upper vagina and uterus is the prime feature of the disease,^[1,2] which, in addition, is often found associated with unilateral renal agenesis or dysplasia as well as skeletal malformations. The phenotypic manifestations of MRKH overlap

Case Report

A 25-year-old female presented with complaints of primary amenorrhea. She stated that she became sexually active at 17 years and had noted changes associated with puberty around 14 years of age. She was of short stature (height 90 cm; weight 30 kg), had facial dysmorphism, macrocephaly, short neck, and low hair line. The patient had normal breast development, normal body hair distribution, including pubic and axillary hair. Pelvic examination showed her vulva, labia minora and majora, and clitoris as normal and well estrogenized. The vagina was found to be blindly ending, with the length of 6 cm.

Blood routine and renal function tests were normal.

Access this article online	
Quick Response Code:	Website: www.ijhg.com
	DOI: 10.4103/0971-6866.112928

Address for correspondence: Dr. A. Anand, Department of General Medicine, Aarupadai Veedu Medical College, Kirumampakam - 607 402, Puducherry, India. E-mail: anand10587@yahoo.com

Hormone profile included measurement of follicular stimulating hormone, luteinizing hormone, estradiol, and 17-hydroxyprogesterone, which were all normal, indicating normal hypothalamic-pituitary-ovarian axis. An ultrasound scan of the abdomen and pelvis confirmed a blind vagina and poorly formed uterus and absent left kidney. The single right pelvic kidney was within normal limits for size and appearance. Magnetic resonance imaging abdomen revealed absent uterus and vagina presence of ovary at both para iliac region and absent left kidney; Grade-I spondylolisthesis with bilateral spondylosis at L5-S1 level [Figures 1 and 2]. Chromosomal study indicated normal (46, XX) female karyotype [Figure 3], which, obviously, is what differentiates MRKH syndrome from other genital tract development defects such as Turner syndrome (45, 0X) and androgen insensitivity syndrome (46, XY). Two-dimensional echocardiogram carried out was normal. Computed tomography brain carried out showed Dandy Walker malformation with vermian hypoplasia, partial agenesis of corpus callosum, and colpocephaly with obstructive hydrocephalus [Figure 4]. X-ray skull showed Macrocephaly [Figure 5].

Discussion

This patient presented with type II MRKH or Mullerian renal cervical somite (MURCS) association. First sign of MRKH syndrome is a primary amenorrhea in young women presenting otherwise with normal development of secondary sexual characteristics and normal external genitalia, with normal and functional ovaries, and karyotype (46, XX) without visible chromosomal anomaly. MRKH may be isolated (type I) however, it is more frequently associated with renal, vertebral, and to a lesser extent, auditory, and cardiac defects (MRKH type II or MURCS association).^[3]

This syndrome is subdivided in two types: Type I (isolated) or Rokitansky sequence (OMIM 277000), and type II or MURCS association (i.e., Mullerian duct aplasia, renal dysplasia, and cervical somite anomalies) (OMIM 601076).^[3,4] Type II or MURCS shows renal (unilateral agenesis, ectopia of kidneys or horseshoe kidney); Skeletal in particular, vertebral (Klippel-Feil anomaly; fused vertebrae, mainly cervical;

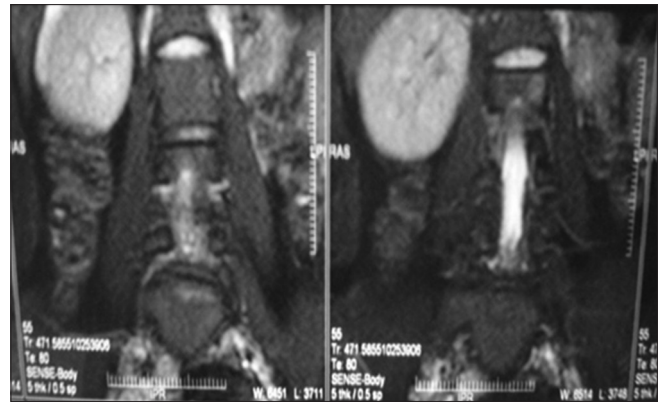


Figure 1: Magnetic resonance imaging abdomen showing absent uterus and vagina. Absent left kidney. Grade-I spondylolisthesis with bilateral spondylosis at L5-S1 level

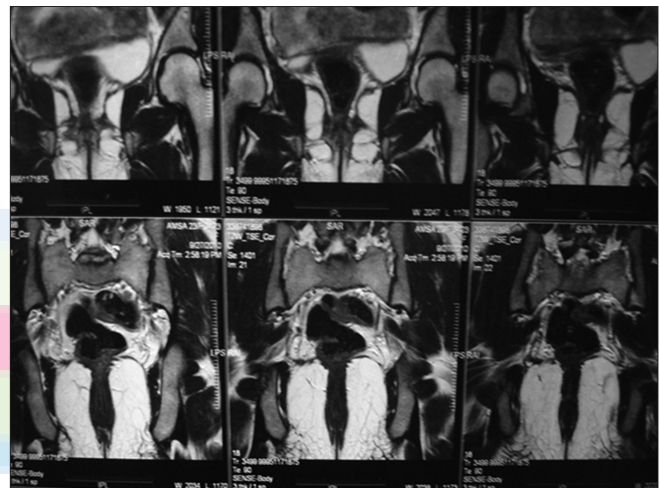

Figure 2: Magnetic resonance imaging abdomen - Visualization of gonads with features s/o of ovary at both para iliac region

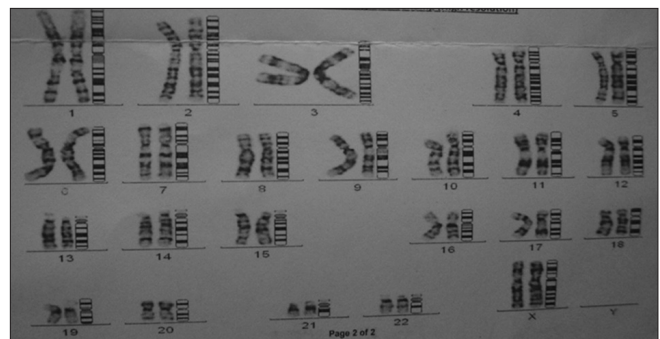


Figure 3: Karyotype study shows (46, XX) chromosome

scoliosis); Hearing defects (stapedial ankylosis); More rarely, cardiac and digital anomalies (aorto-pulmonary window, atrial septal defect and conotruncal defects such as pulmonary valvular stenosis or tetralogy of Fallot, syndactyly, polydactyly, Holt-Oram syndrome).

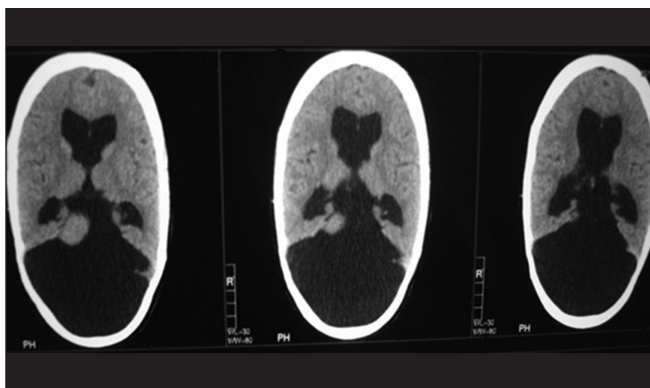


Figure 4: Computed tomography brain shows dandy walker malformation with vermian hypoplasia. Partial agenesis of corpus callosum and colpocephaly with obstructive hydrocephalus

MURCS association is the most severe form of the disorder may be attributed to an alteration of the blastema of the cervicothoracic somites and the pronephric ducts which, by the end of the 4th week of fetal life, have an ultimately spatial relationship.^[4] These overall features clearly differentiate the MRKH syndrome from other defects of genital tract development such as androgen peripheral insensitivity patients (46, XY) or Turner's syndrome patients (45, X).^[5] Our patient had a blind vagina and poorly formed uterus, absent left kidney, macrocephaly, Dandy Walker malformation with vermian hypoplasia with obstructive hydrocephalus with a normal (46, XX) female karyotype study. To the best of our knowledge, there are only few such cases reported, hence we report this case.

Conclusion

Incidence of the MRKH syndrome/MURCS association has probably been under-evaluated mainly because it has, until recently, been seen as a female-specific and sporadic disorder. Isolated features of the triad of main malformations, including kidney agenesis and/or skeletal defects, were consequently not investigated in all probands relatives, including males who can also be affected. This is understandable given the incomplete degree of penetrance, variable expressivity, and similarities of this syndrome with other genetic disorders. Treatment which consists in creating a neo vagina^[6] is generally offered to patients

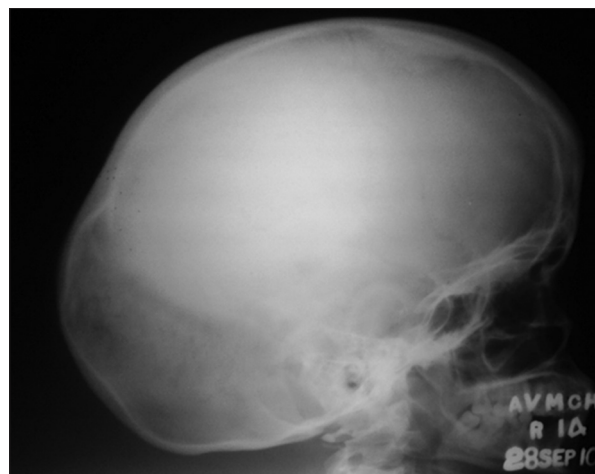

Figure 5: X-ray skull showing macrocephaly

when they are ready to start sexual activity. Moreover, everyday improvement of medical technologies allows, in many countries, women to appeal for *in vitro* fertilization and surrogate pregnancy to bypass the absence of inner genital tract. The number of such women will probably increase with time. This is why characterization of the genetic events responsible for this syndrome is of major importance.

References

1. Griffin JE, Edwards C, Madden JD, Harrod MJ, Wilson JD. Congenital absence of the vagina. The Mayer-Rokitansky-Kuster-Hauser syndrome. *Ann Intern Med* 1976;85:224-36.
2. Folch M, Pigem I, Konje JC. Müllerian agenesis: Etiology, diagnosis, and management. *Obstet Gynecol Surv* 2000;55:644-9.
3. Braun-Quentin C, Billes C, Böwing B, Kotzot D. MURCS association: Case report and review. *J Med Genet* 1996;33:618-20.
4. Duncan PA, Shapiro LR, Stangel JJ, Klein RM, Addonizio JC. The MURCS association: Müllerian duct aplasia, renal aplasia, and cervicothoracic somite dysplasia. *J Pediatr* 1979;95:399-402.
5. Jones HW Jr, Mermut S. Familial occurrence of congenital absence of the vagina. *Am J Obstet Gynecol* 1972;114:1100-1.
6. Roberts CP, Haber MJ, Rock JA. Vaginal creation for Müllerian agenesis. *Am J Obstet Gynecol* 2001;185: 1349-52.

Cite this article as: Pai A, Shakir M. Mayer-Rokitansky-Kuster-Hauser syndrome type II: A rare case. *Indian J Hum Genet* 2013;19:113-5.

Source of Support: Nil, **Conflict of Interest:** None declared.