

Familial clustering of a rare syndrome

Jayashree Nadkarni, Hari Ganesh, Rashmi Dwivedi

Department of Pediatrics, Gandhi Medical College and Associated Kamla Nehru Hospital, Bhopal - 462 016, M.P., India

Ectrodactyly, ectodermal dysplasia and cleft palate syndrome is a rare autosomal dominant multiple congenital anomaly syndrome with variable expressivity and reduced penetration. The cardinal features are cleft palate/lip, lobster hand deformity, sparse hypopigmented hair, dry scaly skin, and lacrimal and urogenital anomalies. A neonate presented to us with typical features, his mother and other two siblings were also affected.

Key words: EEC, ectrodactyly, variable presentations

Introduction

The term EEC syndrome was coined by Rudiger *et al.*, and consists of ectrodactyly (E) and ectodermal dysplasia (E), and cleft lip/palate (C).^[1] Other features include peg-shaped teeth with enamel hypoplasia, conductive deafness, lacrimal duct, and urogenital and neurological anomalies. The syndrome results from a developmental abnormality that simultaneously affects the ectodermal and mesodermal tissues.^[2] Reports of the classical triad of anomalies in families, especially in Indian literature, are few. The inheritance of this condition is autosomal dominant, but there is genetic heterogeneity, variable expressivity, and reduced penetrance accounting for the clinical variability even in the same families, thus making genetic counseling difficult.

Case Report

A one-day-old neonate was referred to our centre for multiple congenital anomalies and prematurity. He was the third among the offsprings, born to nonconsanguineous parents. At the time of conception, mother's and father's ages were 26 and 34 years, respectively. It was a 35 week preterm neonate born by normal vaginal hospital delivery with no significant antenatal history. At birth, the baby had immediate cry.

On examination, he weighed 1.6 kg, with a length of 41 cm and head circumference was 30.5 cm. The skin was dry and scaly, more so on the upper trunk, face, hands, and feet. The hair was sparse, lusterless, and hypopigmented with frontal alopecia. Eyebrows were also thin and sparse. Skeletal anomalies were ectrodactyly with a typical lobster/claw hand—foot deformity. He also had unilateral cleft lip and palate. There was no midfacial hypo- or hyperplasia. Ophthalmological evaluation revealed loss of cilia, with a wrinkled appearance of upper and lower lids on both sides and normal lacrimal puncta. The visual acuity, cornea, fundus, and inner and outer canthal distances were normal. There were no auditory, urogenital, or neurological anomalies on clinical examination.

Routine investigations were within normal limits. X-rays of the hands and feet showed radiological findings corresponding to the clinical features. X-ray spine ruled out spina bifida. There was no urogenital anomaly on ultrasonography.

Similar skeletal abnormalities were present in the mother and the elder sibling (5-year-old female), though they did not have cleft palate [Figure 1] The second

Access this article online

Quick Response Code:



Website:

www.ijhg.com

DOI:

10.4103/0971-6866.82189

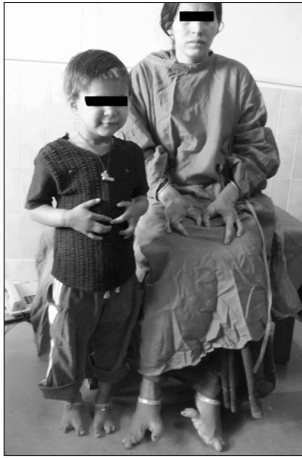

Figure 1: Mother and elder sibling with typical limb deformities.

sibling died at the age of 4 days and according to the mother, he also had similar hand deformities, but no orofacial deformity [Figure 2].

Discussion

The EEC syndrome is a rare autosomal dominant disorder with variable expressivity and reduced penetrance.^[3] The central reduction defect of the hands and feet known as ectrodactyly, split hand/split foot malformation, or lobster-claw, occurs in approximately 1 in 18 000 newborns. Other modes of inheritance have also been noted. The karyotype is usually normal. This disorder has been attributed to mutations in a gene encoding the p63. P63 is a transcription factor that regulates the activity of the tumor suppressor gene TP53. Based on linkage studies and the analysis of chromosomal abnormalities, three loci have been identified in humans.^[4] It is a type of ectodermal dysplasia with variable involvement of skin, hair, teeth, and nails

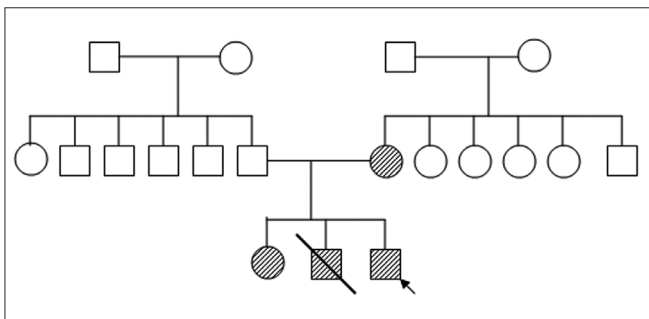


Figure 2: Pedigree Chart of the family.

[Figure 3]. Ectodermal dysplasia may manifest as diffuse dryness and hypopigmentation of skin, hypopigmented and scanty hair, dysplastic nails, and abnormal dentition. Ophthalmologic manifestations include entropion, telecanthus, absence of lacrimal puncta, absence of lashes, blepharitis, corneal opacification, and neovascularization. Other ectodermal anomalies include mild hypohidrosis; coarse, dry hair with hypotrichosis; xerostomia; dystrophic nails; dental enamel hypoplasia; and microdontia.^[5] Associated defects include conductive deafness, choanal atresia, and abnormalities of the genitourinary tract such as megaureter, duplicating collecting system, diverticuli, ureterocele, etc.^[6]

Ectrodactyly refers to variable deformities of hand and feet, having a common central split or cleft, but its occurrence is not obligatory. In a meta-analysis of 230 published cases (116 familial and 114 sporadic), ectrodactyly was found in 84%, ectodermal dysplasia in 77%, clefts in 68%, and anomalies of lacrimal ducts in 59%. Urogenital defects were reported in 52 patients and conductive hearing loss in 33. Isolated cases were more severely affected than familial cases.^[7] Our case presented with all the three cardinal features but no eye or genitourinary abnormalities. It is probable that some of the manifestations may take some time to develop, hence are not seen in this neonate. Also, variability in the phenotype within the same family is seen. Annren *et al.*, suggested that low birth weight and polysyndactyly (without ectrodactyly) may be features of the EEC syndrome.^[8] Jindal G. reported a 6 and half-year-old boy

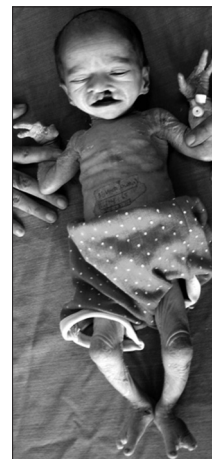

Figure 3: Showing dry scaly skin, sparse hair and eyebrows, cleft palate and limb deformities.

with similar hand foot deformity whose sibling, a term female stillbirth also had a similar anomaly, but neither had other associated defects.^[9]

Fryns *et al.*, reported variable manifestations of EEC in 2 families, confirming that no symptom is obligatory for the diagnosis. In the absence of cleft lip/palate, EEC patients have a characteristic facial morphology with maxillary hypoplasia, short philtrum, and broad nasal tip. Interfamilial variability was significantly greater than intrafamilial variability, pointing to genetic (allelic?) heterogeneity. The penetrance of the EEC mutation is between 93 and 98%. No signs of anticipation were apparent.^[10] The variable expressivity accounts for phenotypic variability in the affected members of the same family. Management of the cases requires multidisciplinary approach and reassurance regarding the low risk of mental handicap.

References

- Rudiger RA, Haase W, Passrge E. Association of ectrodactyly, ectodermal dysplasia and cleft lip/palate. *Am J Dis Child* 1970;120:160-3.
- Smith S. Recognizable patterns of human malformations, 6th ed. USA: Elsevier Saunders Publication; 2006. p. 330.
- Walker JC, Clodius L. The syndromes of cleft lip, cleft palate and lobster claw deformities of hands and feet. *Plast Reconstr Surg* 1963;32:627-36.
- Celli J, Duijf P, Hamel BC, Bamshad M, Kramer B, Smits AP, *et al.* Heterozygous germline mutations in the p53 homolog p63 are the cause of EEC syndrome. *Cell* 1999;99:143-53.
- Buss PW, Hughes HE, Clarke A. Twenty-four cases of the EEC syndrome: Clinical presentation and management. *J Med Genet* 1995;32:716-23.
- Nardi AC, Ferreira U, Netto NR Jr, Magna LA, Rodini ES, Richieri-Costa A. Urinary tract involvement in EEC syndrome: A clinical study in 25 Brazilian patients. *Am J Med Genet* 1992;44:803-6.
- Roelfsema NM, Cobben JM. The EEC syndrome: A literature study. *Clin Dysmorph* 1996;5:115-27.
- Anneren G, Andersson T, Lindgren PG, Kjartansson S. Ectrodactyly, ectodermal dysplasia and cleft lip/palate (EEC): The clinical variation and prenatal diagnosis. *Clin Genet* 1991;40:257-62.
- Jindal G, Parmar VR, Gupta VK. Ectrodactyly/split hand feet malformation. *Indian J Hum Genet* 2009;15:140-2.
- Fryns JP, Legius E, Dereymaeker AM, Van den Berghe H. EEC syndrome without ectrodactyly: Report of two new families. *J Med Genet* 1990;27:165-8.

- Rudiger RA, Haase W, Passrge E. Association of ectrodactyly, ectodermal dysplasia and cleft lip/palate. *Am J Dis Child* 1970;120:160-3.
- Smith S. Recognizable patterns of human malformations,

Cite this article as: Nadkarni J, Ganesh H, Dwivedi R. Familial clustering of a rare syndrome. *Indian J Hum Genet* 2011;17:26-8.

Source of Support: Nil, **Conflict of Interest:** None declared.

Author Help: Reference checking facility

The manuscript system (www.journalonweb.com) allows the authors to check and verify the accuracy and style of references. The tool checks the references with PubMed as per a predefined style. Authors are encouraged to use this facility before submitting articles to the journal.

- The style as well as bibliographic elements should be 100% accurate to get the references verified from the system. A single spelling error or addition of issue number / month of publication will lead to error to verifying the reference.
- Example of a correct style
Sheahan P, O'leary G, Lee G, Fitzgibbon J. Cystic cervical metastases: Incidence and diagnosis using fine needle aspiration biopsy. *Otolaryngol Head Neck Surg* 2002;127:294-8.
- Only the references from journals indexed in PubMed would be checked.
- Enter each reference in new line, without a serial number.
- Add up to a maximum 15 reference at time.
- If the reference is correct for its bibliographic elements and punctuations, it will be shown as CORRECT and a link to the correct article in PubMed will be given.
- If any of the bibliographic elements are missing, incorrect or extra (such as issue number), it will be shown as INCORRECT and link to possible articles in PubMed will be given.